

Marija Gašpar¹, Ana Glavina¹, Kristina Grubišić², Ivan Sabol³, Mirela Bušić¹, Marinka Mravak-Stipetić¹

Stanje usne šupljine kod osoba s transplantiranim bubregom

The Oral Cavity State in Renal Transplant Recipients

¹ Zavod za oralnu medicinu Stomatološkog fakulteta Sveučilišta u Zagrebu
Department of Oral medicine, School of Dental Medicine, University of Zagreb, Zagreb, Croatia
² Institut Ruder Bošković Zagreb, Croatia
Rudjer Bošković Institute, Zagreb, Croatia
³ Nacionalni koordinator za transplantaciju Ministarstva zdravlja RH
National Transplant Coordinator, Ministry of Health, Republic of Croatia

Sažetak

Svrha: Bolesnicima s transplantiranim čvrstim organom mogu se pojaviti mnogobrojne i različite komplikacije u ustima zbog oslabljene imunosti i nuspojava na lijekove. Svrha ovog istraživanja bila je ispitati učestalost i vrstu oralnih lezija kod bolesnika s transplantiranim bubregom, odrediti stanje zuba i oralne higijene, oralne lezije povezane s lijekovima koje pacijenti uzimaju prije transplantacije i nakon te operacije, te koliko često pacijenti u poslijetransplantacijskom razdoblju posjećuju stomatologa. **Ispitanici i postupci:** Istraživanje je trajalo dvije godine, a uključeno je bilo 100 ispitanika s transplantiranim bubregom tijekom njihovih redovitih kontrola u Zavodu za nefrologiju i dijalizu KBC-a Zagreb i u Zavodu za oralnu medicinu Stomatološkog fakulteta Sveučilišta u Zagrebu te 100 nasumce odabranih kontrolnih ispitanika iz Zavoda za endodonciju i restaurativnu stomatologiju Stomatološkog fakulteta Sveučilišta u Zagrebu. **Rezultati:** Rezultati su pokazali značajno veću učestalost oralnih lezija kod bolesnika s transplantiranim bubregom (31 %) u usporedbi s kontrolnim ispitanicima. Najčešće promjene bile su eritem, keratotične lezije na sluznici i hiperplazija gingive. Prosječna vrijednost KEP indeksa bila je značajno niža kod bolesnika s transplantiranim bubregom negoli u kontrolnoj skupini. Trećina bolesnika imala je subjektivni osjećaj suhoće usta. Oralna higijena sveukupno je bila loša i samo malobrojni ispitanici koristili su se dodatnim proizvodima za higijenu usta. Većina pacijenata nakon transplantacije nije posjetila stomatologa. **Zaključak:** Bolesnici s presađenim bubregom trebaju sveobuhvatnu i redovitu stomatološku skrb prije transplantacije i nakon nje, a doktor dentalne medicine neizostavno treba biti član multidisciplinarnog tima medicinskih stručnjaka.

Zaprimljen: 15. svibnja 2015.

Prihvaćen: 25. srpnja 2015.

Adresa za dopisivanje

Prof.dr.sc. Marinka Mravak-Stipetić
Sveučilište u Zagrebu
Stomatološki fakultet
Zavod za oralnu medicinu
Gundulićeva 5, 10 000 Zagreb, Croatia
mravak@sfzg.hr

Ključne riječi

presadivanje bubrega; imunosupresija; oralne manifestacije; gingiva, hiperplazija; DMF indeks; oralna higijena

Uvod

U proteklih 50 godina presađivanje organa postalo je diljem svijeta opće prihvaćena i uspješna metoda liječenja koja je stotinama tisuća bolesnika omogućila najveću terapijsku dobrobit (1). Zahvaljujući plemenitoj odluci o darivanju organa (152 darivatelja), u 2013. godini u Hrvatskoj su presađena 363 organa – 208 bubrega, 115 jetara, 33 srca i 7 gušterača (2).

Kako su svi pacijenti s transplantiranim organom pod stalnom imunosupresivnom terapijom radi prevencije kroničnog odbacivanja organa, podložniji su i razvoju sustavnih komplikacija i oralnih lezija. Lezije u usnoj šupljini mogu nastati kao izravna posljedica imunosupresije ili interakcije lijekova (3, 4). Među najčešćim komplikacijama imunosupresije različite su virusne infekcije uzrokovane virusima *Herpes simplex*, *Varicellazoster*, citomegalovirusom i Epstein-Barrovim virusom s kojim je povezana i pojava vlasaste leukoplakije (5). Dokazana je, a i dosta je česta, infekcija humanim papiloma virusom, osobito ako je riječ o starijim bolesnicima s transplantiranim bubregom (6), povećana je također učestalost infekcije uzrokovane gljivicom roda *Candida* (7) te razli-

Introduction

Over the past 50 years, organ transplantation has become a widely accepted and successful method of treatment around the world that has enabled hundreds of thousands of patients to receive the greatest therapeutic benefit (1). Owing to the noble act of donating organs (152 donors), the total of 363 organs were transplanted in Croatia in 2013, 208 renal transplants, 115 livers, 33 hearts and 7 pancreases (2).

Since all of the transplant recipients are under continuous immunosuppressive therapy for the prevention of chronic rejection, they are also more susceptible to the development of systemic complications and are at increased risk of orofacial diseases. Lesions in the oral cavity may arise as a direct result of immunosuppression or drug interactions (3, 4). Among the most common oral complications of immunosuppression are different viral infections caused by the herpes simplex virus, varicella zoster virus, cytomegalovirus and Epstein Barr virus associated with the development of hairy leukoplakia (5). An increased incidence of infection caused by the human papillomavirus, particularly in elderly patients with a renal transplant (6) and increased incidence of fungal

čitih bakterijskih infekcija (8). Kao posljedica interakcije ciklosporina A i blokatora kalcijevih kanala, gotovo redovito se svim bolesnicima koji primaju ovu kombinaciju lijekova pojavljuje hiperplazija gingive (9). Kod osoba s transplantiranim bubregom opisana je pojava raka usnice i usne šupljine (10), a rjeđe poslijetransplantacijski limfoproliferativni poremećaj, oralne ulceracije i lihenoidne reakcije (11). Uz već dokumentirane oralne lezije, opisana je pojava novih entiteta s obilježjima orofacijalne granulomatoze, osobito kod djece s transplantiranim solidnim organom (12). S obzirom na porast broja transplantacija posljednjih godina, veća je mogućnost da i doktoru dentalne medicine u ordinaciju dođe pacijent s presađenim organom kojemu je potrebna posebna stomatološka skrb kako zbog njegova stanja i terapije tako i zbog mogućih promjena u ustima zbog lijekova ili oštećenog imunskog odgovora organizma (1, 2, 13). Stoga je svrha ovog istraživanja bila ispitati:

- a) učestalost i vrstu oralnih lezija,
- b) stanje oralne higijene i stupanj salivacije,
- c) nalaz lezija, povezano s uzimanjem lijekova i vremenom koje je prošlo nakon transplantacije
- d) učestalost odlaska bolesnika s transplantiranim bubregom na rutinski stomatološki pregled nakon transplantacije.

Ispitanici i metode

Istraživanje je trajalo dvije godine (2011. i 2012.) nakon što ga je odobrilo Etičko povjerenstvo Kliničkoga bolničkoga centra Zagreb i Etičko povjerenstvo Stomatološkog fakulteta Sveučilišta u Zagrebu. Svakom ispitaniku objašnjen je protokol istraživanja i, nakon što je potpisao informirani pristanak, bio je uključen u istraživanje. Ukupno je sudjelovalo 100 ispitanika s transplantiranim bubregom i 100 nasumce odabranih kontrolnih ispitanika, dakle onih koji nisu imali presađen organ niti su bili pod imunosupresivnom terapijom. Od svih sudionika uzeti su anamnestički podatci i popis lijekova koje uzimaju nakon zadnjeg posjeta stomatologu te je obavljen detaljni klinički intraoralni pregled. Svi podatci zabilježeni su u anketnom listu.

Stomatološka anamneza uključivala je podatke o oralnoj higijeni, učestalosti pranja zuba i upotrebi oralnih antiseptika. Od bolesnika su zatraženi i podatci o suhoći usta na temelju pet sljedećih pitanja: *Imate li često osjećaj suhoće usta?*, *Jesu li vam usta suha tijekom jela?*, *Gutate li teško suhu hranu?*, *Morate li tijekom jela piti tekućinu kako biste lakše progutali hranu?*, *Imate li osjećaj da vam stalno nedostaje sline ili ne?* Potvrđan odgovor na najmanje jedno od pet postavljenih pitanja znači da bolesnik pati od suhoće usta (15). Za procjenu kvalitete sline proveden je i vitroadhezijski test stomatološkim zrcalom (16).

Pacijentima s transplantiranim bubregom oralni pregled obavljen je tijekom njihova redovitog kontrolnog posjeta ambulantom Zavoda za nefrologiju i dijalizu Kliničkoga bolničkoga centra Zagreb i u Zavodu za oralnu medicinu Stomatološkog fakulteta Sveučilišta u Zagrebu. Kontrolnu skupinu činili su nasumce odabrani pacijenti koji su došli radi liječenja zuba u Zavod za endodonciju i restaurativnu sto-

infections caused by the fungus *Candida* species (7) has been shown, as well as a variety of bacterial infections (8). As a result of the interaction of cyclosporine A and calcium channel blockers, almost regularly in all patients receiving this combination of drugs, gingival hyperplasia appears (9). In patients with a renal transplant, lip and oral cancer are also described (10) and less frequently post-transplant lymphoproliferative disorders, oral ulceration and oral lichenoid reactions (11). In addition to the documented oral lesions, the emergence of new entities with characteristics of orofacial granulomatosis is described, especially in children with solid organ transplantation (12). Given the increase in the number of transplants in recent years, the possibility that the general dentist will encounter a transplant patient who requires special dental care because of the condition and treatment and because of possible oral lesions related to medication or immune response is greater (1, 2, 13). Therefore, the aim of our study was to investigate a) the prevalence and type of oral lesions, b) dental and oral hygiene status and salivation rate, c) oral lesions related to drugs and the time of renal transplantation, and d) the frequency of patient's visits to the dentist in the post-transplant period.

Subjects and methods

The study was conducted in the period of two years (2011 and 2012), after approval by the Ethics Committee of the Clinical Hospital Center Zagreb and the Ethics Committee of the School of Dental Medicine, University of Zagreb. The study included 100 patients with renal transplant, and another 100 randomly selected control subjects who were neither organ recipients nor under immunosuppressive therapy.

The study protocol was explained to each patient, and after signing the informed consent, the patients were included in the study.

Transplant patient medical data included the period after the transplantation, the list of patient's medications, and information about the last visit to the dentist. Clinical oral examination was performed in all transplant patients and controls (14). Data were recorded in a structured questionnaire.

Dental history included information about oral hygiene, the frequency of teeth brushing and flossing and use of mouth sustainers. Patients were asked about xerostomia symptoms and an affirmative response to at least one of the five following questions was used to confirm the subjective manifestations of xerostomia: "Does your mouth usually feel dry?", "Does your mouth feel dry when eating a meal?", "Do you have difficulty swallowing dry food?", "Do you sip liquids to aid in swallowing dry food?" and "Is the amount of saliva in your mouth too little most of the time, or do you not notice it?" (15). Along with subjective statements we applied the dental mirror adhesion test for more qualitative assessment of oral dryness. The test was performed by pressing a dental mirror on the dorsal side of the tongue (16).

In renal transplant patients, oral examination was performed during their regular control visit to the Department

matologiju Stomatološkog fakulteta Sveučilišta u Zagrebu. Oralni pregled sluznice i zuba obavile su suautorice ovog rada M. G., A. G. i K. G.

Stomatološki pregled svih ispitanika obuhvatio je pregled oralne sluznice i zuba, a zabilježeno je i stanje oralne higijene. Pregled zuba obavljen je stomatološkom sondom i zrcalom. Pritom je osvijetljenje usne šupljine, tijekom oralnog pregleda bolesnika u ambulantama Zavoda za dijalizu Kliničkog bolničkog centra Zagreb, provedeno prema preporuci Svjetske zdravstvene organizacije (17), a u ambulantama Stomatološkoga fakulteta pregled se obavljao u stomatološkoj jedinici. Kriterij za odabir ispitanika bio je dobna granica od 18 godina. Pacijenti na dijalizi nisu bili uključeni u istraživanje.

Promjene na sluznici usne šupljine razvrstali smo na osnovi kliničkih i morfoloških kriterija u pet skupina (17):

- 1.) eritem,
- 2.) hiperkeratozu,
- 3.) erozivno-ulcerozne promjene,
- 4.) hiperplaziju gingive i
- 5.) ostalo.

U kategoriji *ostalo* navedene su morfološke promjene poput hemangioma, obloženog jezika, geografskog jezika i pigmentacija te kemijskih i mehaničkih oštećenja sluznice. Topografija oralnih lezija zabilježena je prema shemi Svjetske zdravstvene organizacije (17).

Hiperplazija gingive klasificirana je u tri stupnja prema Pernuovoj modifikaciji Angelopoulosova i Goazova indeksa (18):

- stupanj 0 (S – 0; normalna gingiva),
- stupanj 1 (S – 1; zadebljanje marginalne gingive koje prekriva jednu trećinu krune zuba),
- stupanj 2 (S – 2; povećanje marginalne gingive koja prekriva trećinu krune zuba),
- stupanj 3 (S – 3; značajno povećanje marginalne gingive koja prekriva više od polovine krune zuba i okolnu pričvrstnu gingivu).

Status zuba procijenjen je KEP indeksom, ne uključujući treće molare (19) (KEP = K – karijes, E – ekstrahirani zub, P – zub s ispunom).

Stupanj oralne higijene određen je svim ispitanicima prema Silnessand-Löevu indeksu plaka (20) osim kod 13 bezubih koji su se koristili totalnim zubnim protezama. Zabilježena je količina zubnoga plaka i kamenca na zubima 16, 12 i 24 u gornjoj čeljusti te na zubima 36, 32 i 44 u donjoj čeljusti i to na sve četiri plohe zuba – bukalnoj, lingvalnoj, mezijalnoj i distalnoj. Debljina naslaga ocijenjena je stupnjevi- ma od 0 do 3:

- 0 – nema plaka i zubnog kamenca;
- 1 – tanki sloj plaka na vratu zuba neposredno uz rub gingive; plak je vidljiv jedino s pomoću plakarevelatora i struganjem zuba sondom;
- 2 – umjerena nakupina plaka na donjoj trećini zuba iznad ruba gingive koji seže i unutar gingivnoga pseudodžepa;
- 3 – obilna nakupina plaka koji prekriva više od polovine zuba i seže u gingivni pseudodžep.

Stupnjevi sa svih četiriju ploha svakoga zuba zbrojeni su i podijeljeni s četiri kako bi se dobila srednja vrijednost indeksa plaka za svaki zub. Indeks plaka za svakog ispitanika

of Nephrology and Dialysis, University Hospital Centre Zagreb and the Department of Oral Medicine, School of Dental Medicine, University of Zagreb. The control group consisted of randomly selected patients who came for regular dental treatment at the Department of Endodontics and Restorative Dentistry, School of Dental Medicine, University of Zagreb. Oral and dental examinations were performed by the authors of this study M.G., A.G., K.G.

In all patients, clinical oral examination included the examination of oral mucosa, teeth and oral hygiene status which was carried out with a dental mirror and dental probe. Lighting was provided with exploratory examination light as recommended by WHO (17), while in dental office, the examination was performed in the dental chair. Inclusion criterion for all the patients was the minimum 18 years of age. Patients on dialysis were not included in the study.

Changes on the oral mucosa were classified according to morphological criteria in 5 groups (17): 1) erythema, 2) hyperkeratosis, 3) erosive-ulcerous lesions, 4) gingival hyperplasia, and 5) other. Under category "other" morphological lesions such as haemangioma, hairy tongue, geographic tongue, pigmentation and chemical and mechanical damage of oral mucosa were listed. Topography of oral lesions was observed and recorded according to the scheme of World Health Organization (17).

Gingival hyperplasia was classified in 3 stages according to Pernu's modification of Angelopoulos's and Goaz's index (18) as follows:

- grade 0 (S-0; normal gingiva),
- grade 1 (S-1; thickened marginal gingiva that covers one third of the crown),
- grade 2 (S-2; increased the marginal gingiva that covers half of the crown),
- grade 3 (S-3; a significant increase of the marginal gingiva which covers more than half of the tooth crown and the surrounding retaining gum).

Dental status was assessed by DMFT index, not including the third molars (19).

The degree of oral hygiene was determined according to the Silness-Löe plaque index (20), in all subjects except 13 patients with complete dentures. The measurement was based on recording both the soft debris and mineralized deposits on the teeth 16, 12, 24 in the upper jaw and 36, 32, 44 in the lower jaw. Missing teeth were not substituted. Each of the four surfaces of the teeth (buccal, lingual, mesial, distal) was given a score from 0-3:

- 0 – No plaque,
- 1 – A film of plaque adhering to the free gingival margin and adjacent area of the tooth. The plaque may be seen *in situ* only after application of disclosing solution or by using the probe on the tooth surface,
- 2 – Moderate accumulation of soft deposits within the gingival pocket, or the tooth and gingival margin which can be seen with the unaided eye,
- 3 – Abundance of soft matter within the gingival pocket and/or on the tooth and gingival margin.

The scores from the four areas of the tooth were added and divided by four in order to obtain the plaque index for

dobiven je zbrojem indeksa za svih šest zuba i podijeljen sa šest (19).

Patološke promjene na oralnoj sluznici fotografski su dokumentirane, a ispitanici su upućeni u Zavod za oralnu medicinu Stomatološkog fakulteta Sveučilišta u Zagrebu radi daljnje dijagnostike i liječenja.

Svi ispitanici dobili su upute o pravilnom održavanju oralne higijene.

Podatci su organizirani u datoteke (Microsoft Excell, Microsoft Inc., SAD) i statistički obrađeni programom MedCalc V.11 (MedCalcSoftware, Mariakerke, Belgija). Za ispitivanje razlika između kontinuiranih varijabli korišten je t-test za nezavisne uzorke, a značajnost razlika kategorijskih varijabli ispitana je hi-kvadrat testom (χ^2). Kategorijske varijable s više kategorija uspoređivane su Mann-Whitneyevim U-testom za nezavisne uzorke. Korelacije između pojedinih varijabli određene su Spearmanovim koeficijentom korelacije. Statistički značajnima smatrane su vrijednosti $p < 0,05$.

Rezultati

Među 100 pacijenata s transplantiranim bubregom, 62 posto bile su žene, a 38 posto muškarci. Njihova prosječna dob iznosila je $52,48 \pm 13,65$ (raspon dobi od 18 do 74 godine). Od 100 kontrolnih pacijenata 48 posto bile su žene, a 52 posto muškarci, dok je prosječna dob iznosila $49,9 \pm 13,47$ (raspon dobi od 24 do 85 godina).

Promjene na sluznici usne šupljine

Pacijenti s transplantiranim bubregom imali su značajno više oralnih lezija na sluznici usne šupljine (31 %) nego li kontrolna skupina (12 %) (χ^2 test, $p = 0,0019$). Od lezija su češće patile žene (20/62) nego li muškarci (11/38). Prosječna dob pacijenata s promjenama na sluznici bila je $49,42 \pm 15,16$, a kod onih bez oralnih lezija $53,85 \pm 12,79$, ($p > 0,05$).

Distribucija oralnih lezija pronađenih kod pacijenata s transplantiranim bubregom i ispitanika iz kontrolne skupine prikazana je u tablici 1.

Najčešća oralna lezija bio je eritem sluznice, a najrjeđe su bile erozivno-ulcerozne promjene. Promjene na sluznici usne šupljine pojavljivale su se dvije godine nakon transplantacije (slika 1.).

Hiperplaziju gingive imalo je pet ispitanika (četvorica muškaraca i jedna žena) s transplantiranim bubregom, uglavnom mlađe dobi (prosječna dob 38,8 godina). Žene su imale

the tooth. The index for the patient was obtained by summing the indices for all six teeth and dividing by six (19).

Lesions of the oral mucosa were photographically documented, and subjects were referred to the Department of Oral Medicine, School of Dental Medicine, University of Zagreb for further diagnostics and treatment.

All subjects were given the instructions on adequate oral hygiene.

The data were organized into files (Microsoft Excel, Microsoft Inc. U.S.) and statistically analyzed by using MedCalc V.11 program (MedCalc Software, Mariakerke, Belgium). To test the differences between continuous variables, t-test for independent samples was used, while the significance of the differences of categorical variables was tested by using chi-square test (χ^2 test). Mann-Whitney U test for independent samples was used for comparison of categorical variables with more categories. Correlations between individual variables were determined by Spearman correlation coefficient. Level of significance was determined at $p < 0.05$.

Results

Out of 100 renal transplant patients, 62% were women and 38% were men (mean age 52.48 ± 13.65 ; age range 18-74). Out of 100 control patients, 48% were women and 52% men (mean age 49.9 ± 13.47 ; age range 24-85).

Lesions on the oral mucosa

Renal transplant patients have a greater number of oral lesions (31%) than the controls (12%) (χ^2 test, $p=0.0019$). Lesions were more frequently found in women (20/62) than in men (11/38). The average age of patients with oral lesions was 49.42 ± 15.16 , in comparison to patients with no oral lesions 53.85 ± 12.79 ($p>0.05$). The distribution of oral lesions in renal transplant patients and the control group is shown in Table 1.

The most common lesion was mucosal erythema, and the least frequent were erosive-ulcerous lesions. Oral lesions appeared most frequently within two years after transplantation (Figure 1).

Gingival hyperplasia was found in only five renal transplant patients (four men and one woman), mostly in younger patients (the average age was 38.8 years) and with higher severity in women (grade 3) than in men (grade 2 and 1, respectively).

Tablica 1. Lezije oralne sluznice
Table 1 Lesions of the oral mucosa

	xxx • Renal transplant group	Kontrolna skupina • Control group
xxx • Lesions	31.0% ($p=0.0019$)	12.0%
Erosive-ulcerous lesions	3.0%	0.0%
Gingival hyperplasia	5.0%	0.0%
Erythema	13.0% ($p=0.019$)	3.0%
Hyperkeratosis	9.0%	2.0%
Other	16.0%	9.0%

intenzivnije promjene (stupanj 3) u odnosu prema muškarcima (stupanj 1 i 2).

Pojava hiperplazije gingive bila je povezana s količinom i vrstom lijekova (tablica 2.).

Bolesnici s transplantiranim bubregom najčešće su od lijekova uzimali kortikosteroide (88 %), mikofenolatmofetil (84 %), ciklosporin A (75 %) i blokatore kalcijevih kanala (52 %) (tablica 3.). Od 75 bolesnika kojima je bio propisan ciklosporin A, 43 su istodobno uzimali i blokator kalcijevih kanala.

Prema topografiji Svjetske zdravstvene organizacije (17), najčešća lokalizacija hiperplazije gingive je na marginalnoj gingivi u području gornjih i donjih prednjih zuba, u regijama 31, 32, 37 i 38.

The occurrence of gingival hyperplasia was associated with the number and type of the drug (Table 2).

The most commonly used drugs in patients with renal transplant were corticosteroids (88%), mycophenolate mofetil (84%), cyclosporine A (75%) and calcium channel blockers (52%) (Table 3). Out of the 75 patients who were using cyclosporine A, 43 patients were additionally taking calcium channel blockers.

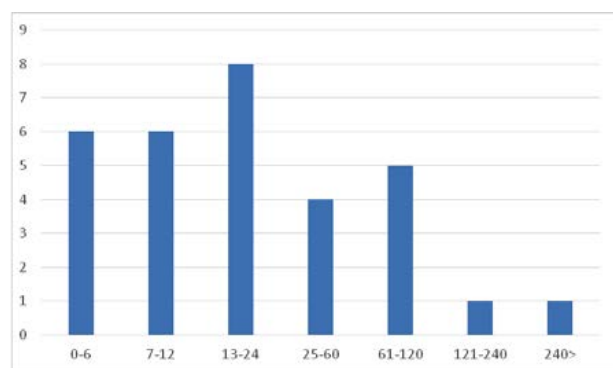
According to the topography of the WHO (17), the most common location of gingival hyperplasia was the marginal gingiva in the upper and lower anterior teeth, in the region of 31, 32, 37, 38.

Tablica 2. Lijekovi koje uzimaju pacijenti s gingivalnom hiperplazijom
Table 2 Medications used by patients with gingival hyperplasia

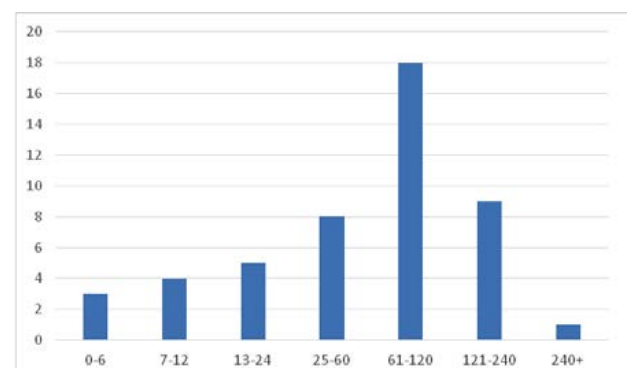
Hyperplasia Grade	Sex	Tacrolimus	Mycophenolate mofetil	Cyclosporine A	Valproic acid	Calcium Channel Blockers	Clonazepam
1	M	Yes	Yes				
1	M	Yes	Yes				
2	M	Yes		Yes		Yes	
2	M		Yes	Yes			
3	F		Yes	Yes	Yes	Yes	Yes

Tablica 3. Prevalencija lijekova koje uzimaju pacijenti s transplantiranim bubregom
Table 3 The prevalence of drugs in patients with renal transplant

	%
Corticosteroids	88
Mycophenolate mofetil	84
Cyclosporine A	75
Antihypertensives	55
Calcium channel blockers antihypertensives	52
Tacrolimus	20



Slika 1. Pojavnost oralnih lezija u odnosu na mjesec nakon transplantacije
Figure 1 Occurrence of oral lesions with respect to time in the months after transplantation



Slika 2. Posjete doktoru dentalne medicine u odnosu na vrijeme nakon transplantacije
Figure 2 Time after transplantation in months and visit to the dentist

Suhoća usta

Suhoća usta zabilježena je kod 33 posto bolesnika s transplantiranim bubregom i 13 posto kontrolnih ($p = 0,001$). Nije bio značajne povezanosti suhoće usta s dobi bolesnika, spolom, oralnim lezijama ili bilo kojim ordiniranim lijekom.

KEP indeks

Prosječni KEP indeks bolesnika s transplantiranim bubregom bio je $14,75 \pm 6,91$, u usporedbi s kontrolnom skupinom ($17,17 \pm 6,23$) i ta je razlika bila statistički značajna (Mann-Whitneyjev U-test, $p = 0,0073$).

Kod ispitanica s transplantiranim bubregom KEP indeks bio je $16,29 \pm 7,41$, a kod ispitanika iznosio je $13,81 \pm 6,47$, bez značajnih razlika. Također nije bilo korelacije između KEP indeksa i vremena proteklog od transplantacije (koeficijent korelacije $r = -0,2$) ni s dobi pacijenta (koeficijent korelacije $r = 0,04$).

Oralna higijena

Indeks plaka kod ispitanika s transplantiranim bubregom iznosio je od 0,6 do 1,9 (prosječna vrijednost $1,02 \pm 0,27$), a kontrolne skupine 0,6 do 1,4 (prosječna vrijednost $1,11 \pm 0,17$) (Mann-Whitneyjev U-test, $p = 0,0001$). Nije nađena korelacija između KEP-a i indeksa plaka kod ispitanika s transplantiranim bubregom (koeficijent korelacije $r = 0,126$). Značajna razlika uočena je u upotrebi antiseptika za usta između ispitanika s transplantiranim bubregom (24 %) i onih u kontrolnoj skupini (62 %) (χ^2 test, $p < 0,0001$). Manje od polovine ispitanika s transplantiranim bubregom (48 %) posjetilo je stomatologa nakon presađivanja, a prosječno razdoblje odlaska bilo je 79 mjeseci (slika 2.).

Rasprava

Ministarstvo zdravstva Republike Hrvatske smatra program transplantacije jednim od svojih strateških ciljeva, te ga u svim provedbenim mjerama zdravstvene reforme tretira kao program od posebnoga državnog interesa. Kao punopravna članica Europske unije, u 2013. godini Hrvatska je osigurala provedbu standarda kvalitete i sigurnosti organa namijenjenih presađivanju utvrđenih u *Direktivi 2010/45/EU Europskoga parlamenta i Vijeća o standardima kvalitete i sigurnosti ljudskih organa namijenjenih transplantaciji* (2). Iako je prva transplantacija organa u Hrvatskoj obavljena 1971., tek nakon 2000. godine zabilježeno je kontinuirano povećanje od 2,7 na 32 (broj donatora na milijun stanovnika) (1,2). Već četvrti put naša se zemlja ističe kao vodeća u svijetu kad je riječ o doniranju organa i transplantaciji. Prema međunarodno prihvaćenim ključnim pokazateljima uspješnosti programa transplantacije, u 2013. godini Hrvatska je bila prva u svijetu prema broju transplantacija bubrega od umrlih donatora (47,7 na milijun ljudi), a druga prema broju darivatelja organa (35 na milijun ljudi) (2).

Bolesnici s transplantiranim bubregom u povećanoj su opasnosti od razvoja oralnih lezija zbog dugotrajne imunosupresivne terapije. Najčešća je hiperplazija gingive, a za ostale lezije podatci u literaturi oskudni su i oprečni (5, 9, 21 – 23).

Oral dryness

The subjective feeling of oral dryness was present in 33% of renal transplant patients and 13% of controls (χ^2 test, $p=0.001$). There was no significant correlation of oral dryness with age, sex, oral lesions or to any drug used by the renal transplant patient.

DMFT index

The average DMFT (decayed, missed, filled teeth) index of the patients with renal transplant was 14.75 ± 6.91 , in comparison to control group 17.17 ± 6.23 and the difference was statistically significant (Mann-Whitney U test, $p=0.0073$).

The renal transplant female patients' DMFT index was 16.29 ± 7.41 , and in male patients 13.81 ± 6.47 , without significant difference. There was no correlation of DMFT index with the time elapsed since transplantation (correlation coefficient $r = -0.2$) nor with the patients' age (correlation coefficient $r = 0.04$).

Oral hygiene

Patients with renal transplant had the plaque index ranging from 0.6 to 1.9 (average 1.02 ± 0.27) and this finding was significantly different from the control group (0.6-1.4; average 1.11 ± 0.17) (Mann-Whitney U test, $p=0.0001$). No significant correlation was found between DMFT index and plaque index in the patients with renal transplant (correlation coefficient $r = 0.126$). Significant difference was found in the use of additional sustainers for oral hygiene between renal transplant patients (24%) and controls (62%) (χ^2 test, $p < 0.0001$). Only 48% of renal transplant patients have visited a dentist after the transplantation, and the average period was 79 months (Figure 2).

Discussion

The Ministry of Health of Croatia recognizes the transplant program as one of its strategic goals, and in all health care reform implementation measures, treats it as a program of special national interest. As a full member of the European Union, in 2013 Croatia ensured the implementation of quality and safety standards of organs intended for transplantation described in the *Directive 2010/45/EU of the European Parliament and of the Council on standards of quality and safety of human organs intended for transplantation* (2).

Although the first organ transplant in Croatia was performed back in 1971, only after the year 2000, a continuous increase (the number of donors per million inhabitants) from 2.7 to 32 was recorded (1, 2). For the fourth time in a row, Croatia has been pointed out as the leading country in the world in organ donation and transplantation. According to internationally adopted key indicators of transplant program success, in 2013 Croatia was the first in the world in the number of renal transplants from deceased donors (47.7 per million people) and the second in the world in the number of actual organ donors (35 per million people) (2).

Renal transplant patients have an increased risk of developing oral lesions due to long-term immunosuppressive therapy. The most commonly described lesion in the liter-

Rezultati našeg istraživanja pokazuju da pacijenti s transplantiranim bubregom imaju značajno više promjena na sluznici usne šupljine (31 %) negoli kontrolna skupina (12 %), što je u skladu s istraživanjima drugih autora (3, 5, 15). No za razliku od istraživanja de la Rose i suradnika (9) u kojemu je prevalencija oralnih lezija bila 60 posto, kod naših ispitanika i u studiji R.M. López-Pintora i suradnika (15) bila je gotovo dvostruko niža.

Vrijeme nakon transplantacije bubrega jest vrijeme koje je proteklo od presađivanja i u kojem je pacijent bio pod utjecajem imunosupresivne terapije, a iznosilo je od jednog do 301 mjeseca. Medijan vremena koje je prošlo od transplantacije kod naših je bolesnika iznosio 60 mjeseci (srednja vrijednost $60,05 \pm 66,61$ mjeseci), slično kao i u studiji R.M. López-Pintora i suradnika (15), a kod de la Rose i njegovih kolega (9) 10 mjeseci. Razlog za pojavu oralnih lezija vrlo brzo nakon transplantacije jesu visoke doze imunosupresiva u prvim mjesecima poslije operacije (15). Razdoblje nakon transplantacije bilo je kraće kod muškaraca ($57,81 \pm 66,69$; $1 - 301$) negoli kod žena ($63,71 \pm 67,36$; $1 - 270$) ($p > 0,05$).

Najučestalija oralna lezija bio je eritem (13 %). U četiri posto slučajeva radilo se o kliničkoj slici protetskoga palatitisa (Newton 1 i Newton 2) s obzirom na topografiju, nošenje potpune gornje proteze i nezadovoljavajuću oralnu higijenu. Ovi ispitanici nastavili su liječenje u Zavodu za oralnu medicinu Stomatološkog fakulteta. Preostalih devet posto eritematoznih promjena uklapalo se u kliničku sliku marginalnog gingivitisa.

Hiperkeratotične promjene na sluznici uočene su kod devet posto bolesnika, a očitovale su se kao diskretne promjene na obraznoj sluznici (prema topografiji WHO-a bile su zahvaćene regije 19 i 20), a dva su pacijenta imala kliničku sliku oralnoga lihenaplanusa. U radu R.M. López-Pintora i suradnika, *Lichen planus* dijagnosticiran je u 0,6 posto slučajeva (15), a u studiji M. Al-Mohaya i njegovih kolega zabilježen je u 3,4 posto slučajeva (5). U istraživanju A.J. Dirschnabela i suradnika hiperkeratotične promjene i *Lichen planus* nisu pronađeni (3).

Hiperplaziju gingive zabilježili smo kod pet posto naših pacijenata. Prema podacima iz literature, prevalencija gingivne hiperplazije ima širok raspon. Tako su G. Rojas i suradnici promjenu zabilježili u samo 10 posto slučajeva (4), M. Sahebamee i njegovi kolege kod sedam posto pacijenata (24), a A. J. Dirschnabel i suradnici u 15,2 posto slučajeva (3). Ostale studije pokazuju veću prevalenciju – čak do 70 posto slučajeva (5). Većina autora nastanak gingivne hiperplazije povezuje s trima skupinama lijekova: imunosupresivima, blokatorima kalcijevih kanala i antikonvulzivima (5, 24 – 26). Blokatori kalcijevih kanala često se propisuju u kombinaciji s imunosupresivima kako bi smanjili njihovu nefrotoksičnost (24). Kombinirana terapija ciklosporina A (CSA) i blokatora kalcijevih kanala pokazuje znatno veću pojavnost gingivne hiperplazije nego kada se ciklosporin A uzima zasebno (5, 24). U našem istraživanju je 75 posto pacijenata uzimalo ciklosporin A. U 57,3 posto slučajeva ciklosporin A propisivao se u kombinaciji s blokatorima kalcijevih kanala. Veća prevalencija gingivne hiperplazije zabilježena je u kom-

ature is gingival hyperplasia while the data for other lesions are scarce and contradictory (5, 9, 21-23).

The results of our study showed that renal transplant patients had significantly more oral lesions (31%) than the controls (12%), which is in line with studies by other authors (3, 5, 15). However, unlike the study by de la Rosa et al. (9) in which the prevalence of oral lesions was 60%, in our patients, as in the study by López-Pintor RM et al. (15), it was almost two times smaller.

Time after renal transplantation is the time that has elapsed since the organ transplantation and in which the patient is under the influence of immunosuppressive therapy. It was from 1 to 301 months. The median time elapsed after the transplantation in our patients was 60 months (average value of 60.05 ± 66.61 months), as in the study by López-Pintor RM et al. (15), while in the study by de la Rosa et al. (9) it was 10 months. The reason for a more frequent occurrence of lesions in a shorter period after transplantation is the high doses of immunosuppressive therapy in the first months after transplantation (15). The period after transplantation was shorter in men (57.81 ± 66.69 ; $1-301$) than in women (63.71 ± 67.36 ; $1-270$) ($p > 0.05$).

The most frequent oral lesions in our patients were erythematous changes (13%). In 4% it pointed to denture stomatitis (Newton 1 and Newton 2) with respect to topography, wearing upper dentures and due to inadequate oral hygiene. These patients continued treatment at the Department of Oral Medicine, School of Dental Medicine. The remaining 9% of erythematous changes pointed to marginal gingivitis.

Hyperkeratotic lesions were found in 9% of renal transplant patients. The most common clinical picture consisted of discrete changes on the buccal mucosa (regions 19 and 20 according to the WHO topography), whereas the two patients had clinical picture of oral lichen planus. In the study by López-Pintor RM et al., lichen planus was found in 0.6% (15) and in the study by Al-Mohaya M. et al. in 3.4% of cases respectively (5), while in the study by Dirschnabel AJ et al., hyperkeratotic changes and lichen planus were not found (3).

Gingival hyperplasia was found in 5% of our patients. According to the literature, the prevalence of gingival hyperplasia has a wide range. Authors Rojas G et al. noted this change in 10% (4), Sahebamee-M et al. in 7% (24) and Dirschnabel AJ et al. in 15.2% of the cases (3). Other studies show a higher prevalence of up to 70% of cases (5). According to most authors, the occurrence of gingival hyperplasia was associated with three drug classes: immunosuppressive agents, calcium channel blockers and anticonvulsants (5, 24-26). Calcium channel blockers are often used in combination with immunosuppressive agents to reduce their nephrotoxicity (27). Combination therapy of cyclosporine A and calcium channel blockers showed a significantly higher incidence of gingival hyperplasia than when cyclosporine A is used alone (5, 24). In our study, 75% of patients were using cyclosporine A. In 57.3%, cyclosporine A was administered in combination with calcium channel blockers. Higher prevalence of gingival hyperplasia was observed in the combina-

binaciji ciklosporina A s amlodipinom, negoli u kombinaciji CSA s nifedipinom (28).

Valproična kiselina kao antikonvulzant odraslim bolesnicima rijetko uzrokuje hiperplaziju gingive, a kad je riječ o djeci, samo je nekoliko dokumentiranih slučajeva (25). U našem istraživanju, 18-godišnjoj pacijentici, koja je uzimala ciklosporin A u kombinaciji s antikonvulzivima (valproičnom kiselinom i klonazepamom) i blokatorom kalcijevih kanala, pojavila se jaka hiperplazija gingive (slika 4.). Naši ispitanici uzimali su sve tri skupine lijekova koji uzrokuju hiperplaziju gingive, što može objasniti veći intenzitet gingivnih promjena. S obzirom na to da je ovo samo jedan slučaj, ovaj bi odnos trebao biti ispitan na većem uzorku.

Istraživanja pokazuju da je prevalencija gingivne hiperplazije tri puta češća kod muškaraca (4, 29) u odnosu prema ženama, što je pokazalo i naše istraživanje (4 muškarca: 1 žena) te kod mlađih osoba (9, 25). To se može objasniti jačim upalnim odgovorom, lošom oralnom higijenom i hormonalnim disbalansom kod bolesnika s transplantiranim bubregom (26). U našem istraživanju uočena je značajna razlika između prosječne dobi pacijenata s hiperplazijom (38,8 godina) i bez nje (53,2 godine) (t-test, $p = 0,02$). Prema podacima iz literature, gingivna hiperplazija najčešće zahvaća gornje i donje prednje zube (9), što je u skladu i s našim nalazom. Zato je za takve bolesnike osobito važna redovita kontrola zubnog plaka i kamenca (30).

Erozivno-ulcerozne promjene nalik na afte zabilježili smo kod tri posto pacijenata, a R.M. López-Pintor i suradnici pronašli su ulcerozne promjene u 2,2 posto slučajeva (15). Jedan od čimbenika za nastanak oralnih lezija nakon transplantacije jest i protokol primjene immunosupresivnih lijekova koji je specifičan za svaki bolnički centar (24). Najčešće korišteni immunosupresiv u našem istraživanju bio je mikofenolatmofetil (84 %).

Bolesnici s transplantiranim bubregom imali su prosječni KEP indeks $14,75 \pm 6,91$, što je gotovo identično nalazima G. Rojas i suradnika (4).

S obzirom na spol, veća prosječna vrijednost KEP indeksa zabilježena je kod žena, za razliku od nalaza u istraživanju G. Rojas i suradnika (4) koji su veći KEP indeks zabilježili kod muškaraca. KEP indeks u našoj studiji treba interpretirati s oprezom, zato što je njegova procjena učinjena bez popratnih RTG snimaka, pa je moguće da je čak i mnogo veći.

Trećina naših bolesnika imala je subjektivni osjećaj suhoće usta, a u studiji R.M. López-Pintora i suradnika zabilježen je u samo 1,4 posto slučajeva (15). Smanjena količina sline, kao nuspojava antihipertenzivnih lijekova, rizični je čimbenik kad je riječ o razvoju raznih infekcija u usnoj šupljini (24).

Prema dobivenim prosječnim vrijednostima indeksa plaka, oralna higijena većine naših bolesnika nije bila zadovoljavajuća, a u istraživanju Garcije de la Rose i suradnika (9) te G. Rojas i njegovih kolega (4) kod većine bolesnika bila je dobra.

Prema našim spoznajama i dostupnim informacijama, u literaturi je vrlo malo podataka o učestalosti posjeta pacijenata stomatologu nakon transplantacije organa. Naši rezultati pokazali su da je samo 48 posto naših pacijenata bilo kod

tion of drugs cyclosporine A with amlodipine than in nifedipine with cyclosporine A (28).

Valproic acid as an anticonvulsant in the rare cases in adult patients causes gingival hyperplasia, and in children there were only a few documented cases (25). In our study, an 18-year old female patient who used cyclosporine A in combination with anticonvulsants (valproic acid and clonazepam) and the calcium channel blocker had severe gingival hyperplasia (Figure 4). All three groups of drugs that cause hyperplasia were used in our patients, which can be associated with the greatest intensity of those changes. Given that this is just one case, this relationship should be tested on a larger sample.

Studies show that the prevalence of gingival hyperplasia is three times more common in men (4, 29) compared to women as revealed in our study (4 males: 1 female) as well as in younger age groups (9, 25). This can be explained by a stronger inflammatory response, poor oral hygiene and hormonal imbalance in renal transplant patients (26). In our study there was a significant difference (t-test, $p=0.02$) between the average age of patients with hyperplasia (38.8 years) and without (53.2 years). According to the literature, gingival hyperplasia, mostly affects the upper and lower anterior teeth (9), which is consistent with our findings. Of particular importance in these patients is regular control of dental plaque and calculus (30).

Erosive-ulcerous lesions (aphthous ulcers), were noted in 3% of patients, while López-Pintor RM et al. found ulcerous lesions in 2.2% of cases (15). One of the causative factors for oral lesions after transplantation is immunosuppressive drug application protocol that is specific to each hospital center (24). The most commonly used immunosuppressive agent in our study was mycophenolate mofetil (84%).

Patients with renal transplant had the average DMFT index of 14.75 ± 6.91 , which is almost identical to the findings of Rojas G et al. (4).

With regard to gender, a higher average value of DMFT index was noted in female patients unlike Rojas G et al. where a higher DMFT index was found in male patients (4). DMFT score in our study should be interpreted with caution while the assessment of DMFT index was done without a radiograph. It is possible that DMFT index would be much higher.

One third of our patients had a subjective feeling of oral dryness, whereas in the study of López-Pintor RM et al. it was recorded in only 1.4% of cases (15). The reduced amount of saliva as a side effect of antihypertensive drugs is a risk factor for the development of various infections in oral cavity (24).

According to the obtained average values of plaque index, oral hygiene in most of our patients was unsatisfactory, while in the study by de la Rosa Garcia et al. (9) and Rojas G et al. (4) in most patients, the oral hygiene was satisfactory.

To our knowledge, there are scarce data from the literature about the patients' frequency of visiting their dentists after organ transplantation. Our results have shown that only 48% of our patients visited a dentist after their transplantation in the period of 1-301 months with an average of 79 months.

stomatologa nakon transplantacije u razdoblju od jednog do 301 mjeseca, s prosjekom od 79 mjeseci.

Zbog imunosupresije, subjektivnog osjećaja suhoće usta i loše oralne higijene, bolesnici su u većoj opasnosti od oralnih lezija (31). Dobiveni rezultati zabrinjavaju i upućuju na nužnost uključivanja stomatologa u poslijetransplantacijski medicinski tim koji se skrbi o pacijentima s presađenim organom. Tijekom poslijetransplantacijskog razdoblja svakodnevna primjena antiseptičkih otopina za usta, te redoviti posjeti stomatologu i antibiotska profilaksa pri indiciranim invazivnim zahvatima, vrlo su važni za zdravlje bolesnika (31).

Može se zaključiti da bolesnici s presađenim bubregom imaju značajno više oralnih lezija koje se pojavljuju unutar dviju godina poslije transplantacije. Najčešće su eritematozne promjene, a rjeđe su hiperkeratotične promjene, hiperplazija gingive i erozivno-ulcerozne lezije. Pojava i intenzitet hiperplazije gingive u izravnoj je vezi s vrstom lijeka koje bolesnik uzima.

Prosječan KEP indeks bio je značajno niži kod bolesnika s transplantiranim bubregom negoli u kontrolnoj skupini i nije utvrđena povezanost s vremenom nakon transplantacije.

Suhoća usta bila je zabilježena kod jedne trećine bolesnika s transplantiranim bubregom.

Općenito, oralna higijena svih bolesnika nije bila zadovoljavajuća. Razlog je, u usporedbi s kontrolnom skupinom, u slabom korištenju ostalih proizvoda za dentalnu higijenu, kao što su zubni konac i otopine za ispiranje usta.

Većina bolesnika s transplantiranim bubregom nije posjetila stomatologa nakon presađivanja. Kako bi se spriječila komplikacije i odbacivanje organa, u razdoblju nakon presađivanja, uz praćenje općeg stanja pacijenta, također je važno rano otkrivanje oralnih lezija jer može upozoriti na moguće komplikacije medikamentnog liječenja ili na pojavu bolesti zbog odbacivanja presatka (GVHD – od engl. graftversus-hostdisease) te poboljšati kvalitetu života ovih bolesnika. Zato u pravodobnom otkrivanju i liječenju oralnih lezija, nezaobilaznu ulogu ima doktor dentalne medicine (13).

Zahvala

Ovaj je rad dio projekta Ministarstva zdravlja Republike Hrvatske, Instituta za transplantaciju i biomedicinu pod naslovom "Preservation of oral health in patients with transplanted organs" (500-01 / 10-06 / 46, 534-05-1-3 / 1-10 -03). Zahvaljujemo pacijentima i djelatnicima Zavoda za oralnu medicinu i Zavoda za endodonciju i restaurativnu stomatologiju Stomatološkog fakulteta Sveučilišta u Zagrebu. Također zahvaljujemo Zavodu za nefrologiju i dijalizu Kliničkog bolničkog centra Zagreb. Rad je nagrađen Rektovom nagradom za najbolji studentski rad.

Sukob interesa

Nije ga bilo.

Due to immunosuppression, a subjective feeling of oral dryness and poor oral hygiene, the patients have an increased risk of oral lesions (31). The obtained results are worrying and suggest the necessity of dentists' involvement in post-transplant medical team caring for patients with organ transplant. During the post-transplant period daily use of antiseptic solutions as well as regular visits to a dentist and antibiotic prophylaxis during the performance of invasive procedures are of great importance (31).

In conclusion, renal transplant recipients had more oral lesions which occurred within two years after the transplantation.

The most common were erythematous lesions; less frequent were keratotic changes, gingival hyperplasia and erosive-ulcerous lesions.

Gingival hyperplasia is directly associated with the type of drug taken by the patient.

The average DMFT index was significantly lower in patients with renal transplant than in the control group and its association with the time after the transplantation was not found.

Oral dryness was reported in one third of the patients with renal transplant.

In general, oral hygiene was unsatisfactory in all patients because patients used far less additional sustainers for oral hygiene (dental floss and products for dental rinsing) compared to the control group.

Most patients with renal transplant did not visit their dentist after the transplantation. In order to prevent the occurrence of complications and organ rejection in post-transplant period, along with monitoring general condition of the patient, it is equally important to detect and identify oral lesions early, which can point to possible complications of pharmacological treatment or the occurrence of graft versus host disease (GVHD), and improve quality of life in these patients. Therefore, in timely detection and treatment of oral lesions, a crucial role is played by the doctor of dental medicine (13).

Acknowledgement

This paper was written as part of the project of the Ministry of Health, Republic of Croatia, Institute for Transplantation and Biomedicine, entitled "Preservation of oral health in patients with transplanted organs" (500-01 / 10-06 / 46, 534-05-1-3 / 1-10 -03). We thank patients and the employees of the Department of Oral Medicine and the Department of Endodontics and Restorative Dentistry, School of Dental Medicine, University of Zagreb and the Department of Nephrology and Dialysis, Clinical Hospital Centre Zagreb who contributed to this study. This paper was awarded the Rector's award as the best student paper.

Conflict of interest

None declared

Abstract

Aim: Patients with a solid organ transplant can have many different complications in the mouth, as a result of immunosuppression and side effects of drugs. The aim of this study was to examine the frequency and type of oral lesions in renal transplant patients, dental status, oral hygiene, oral lesions related to drugs which patients take and the time of transplantation as well as the frequency of patient's visits to the dentist in the post-transplant period. **Material and methods:** The study was performed in a period of two years and included 100 subjects with a renal transplant during their regular control visits to the Department of Nephrology and Dialysis, Clinical Hospital Centre Zagreb and the Department of Oral Medicine, School of Dental Medicine, University of Zagreb and 100 randomly selected control subjects at the Department of Endodontics and Restorative Dentistry, School of Dental Medicine, University of Zagreb. **Results:** Results showed a significantly higher incidence of oral lesions in patients with renal transplant (31%) compared to control subjects. The most frequent were erythematous (inflammatory changes), keratotic lesions and gingival hyperplasia. The average DMFT index was significantly lower in patients with renal transplant than in the control group. One third of patients had a subjective feeling of dry mouth. Oral hygiene was poor overall, and only a small number of subjects used the additional sustainers for oral hygiene. Most patients did not visit the dentist after the transplantation. **Conclusion:** Renal transplant patients need a comprehensive and regular dental care during the pre- and post-transplant period and a doctor of dental medicine should be part of a multidisciplinary team of medical specialists.

Received: May 15, 2015

Accepted: July 25, 2015

Address for correspondence

Professor Marinka Mravak-Stipetić
University of Zagreb
School of Dental Medicine
Department of Oral Medicine
Gundulićeva 5, 10 000 zagreb, Croatia
mravak@sfzg.hr

Key words

Kidney Transplantation; Immunosuppression; Oral Manifestations; Gingival Hyperplasia; DMF Index, Oral Hygiene

References

- Bušić M. Organ Donation and Transplantation—"Croatian model". *Medix* 2011;17(92/93):144-148.
- MeSH Browser [database on the Internet]. Ministry of health Republic of Croatia. Available from http://www.zdravlje.hr/programi_i_projekti/transplantacijski_program/statistika
- Dirschnebel AJ1, Martins Ade S, Dantas SA, Ribas Mde O, Grégio AM, Alanis LR, et al. Clinical oral findings in dialysis and kidney-transplant patients. *Quintessence Int.* 2011 Feb;42(2):127-33.
- Rojas G, Bravo L, Cordero K, Sepúlveda L, Elgueta L, Díaz JC, et al. Integrity of the Oral Tissues in Patients with Solid-Organ Transplants. Hindawi Publishing Corp. *J Transplant.* 2012;2012:603769.ž
- Al-Mohaya MA, Darwazeh AM, Bin-Salih S, Al-Khudair W. Oral lesions in Saudi renal transplant patients. *Saudi J Kidney Dis Transpl.* 2009 Jan;20(1):20-9.
- Rose B, Wilkins D, Li W, Tran N, Thompson C, Cossart Y, McGeechan K, et al. Human papillomavirus in the oral cavity of patients with and without renal transplantation. *Transplantation.* 2006 Aug 27;82(4):570-3.
- Olczak-Kowalczyk D, Pawłowska J, Garczewska B, Smirska E, Grenda R, Syczewska M, et al. Oral candidiasis in immunosuppressed children and young adults after liver or kidney transplantation. *Pediatr Dent.* 2010 May-Jun;32(3):189-94.
- Murphy OM, Gould FK. Prevention of nosocomial infection in solid organ transplantation. *J Hosp Infect.* 1999 Jul;42(3):177-83.
- de la Rosa E, Mondragon A, Irgoyen ME, Bustamante MA. Oral lesions in a group of kidney transplant patients. *Med Oral Patol Oral Cir Bucal.* 2005 May-Jul;10(3):196-204.
- López-Pintor RM, Hernández G, de Arriba L, de Andrés A. Lip cancer in renal transplant patients. *Oral Oncol.* 2011 Jan;47(1):68-71.
- Petti S, Polimeni A, Berloco PB, Scully C. Orofacial diseases in solid organ and hematopoietic stem cell transplant recipients. *Oral Dis.* 2013 Jan;19(1):18-36.
- Saalman R, Sundell S, Kullberg-Lindh C, Lövsund-Johannesson E, Jontell M. Long-standing oral mucosal lesions in solid organ-transplanted children—a novel clinical entity. *Transplantation.* 2010 Mar 15;89(5):606-11.
- Geddes CC1, Church CC, Collidge T, McCrudden EA, Gillespie G, Matthews E, et al. Management of cytomegalovirus infection by weekly surveillance after renal transplant: analysis of cost, rejection and renal function. *Nephrol Dial Transplant.* 2003 Sep;18(9):1891-8.
- Sollecito, PT. Transplantation medicine. In: Greenberg, MS; Glick, M - editors. *Burket's Oral Medicine. Diagnosis and treatment.* 11th ed. Hamilton, Ontario: BC Decker Inc; 2003. p.503-520.
- López-Pintor RM, Hernández G, de Arriba L, de Andrés A. Comparison of oral lesion prevalence in renal transplant patients under immunosuppressive therapy and healthy controls. *Oral Dis.* 2010 Jan;16(1):89-95.
- Grisius, MM; Fox, PC. Salivary gland diseases. . In: Greenberg, MS; Glick, M - editors. *Burket's Oral Medicine. Diagnosis and treatment.* 11th ed. Hamilton, Ontario: BC Decker Inc; 2003. p. 235-270.
- Kramer IR, Pindborg JJ, Bezroukov V, Infirri JS. Guide to epidemiology and diagnosis of oral mucosal diseases and conditions. World Health Organization. *Community Dent Oral Epidemiol.* 1980 Feb;8(1):1-26.
- Pernu HE, Pernu LMH, Huttunen KRH, Nieminen PA, Knuutila MLE. Gingival overgrowth among renal transplant recipients related to immunosuppressive medication and possible local background factors. *J Periodontol.* 1992 Jun;63(6):548-53.
- MeSH Browser [database on the Internet]. Oral Health Database. Available at: www.mah.se/CAPP/Methods-and-Indices/ .
- Silness J, Løe H. Periodontal diseases in pregnancy.II. Correlation between oral hygiene and periodontal conditions. *Acta Odontol Scand.* 1964 Feb;22:121-35.
- King GN, Healy CM, Glover MT, Kwan JT, Williams DM, Leigh IM, et al. Prevalence and risk factors associated with leukoplakia, hairy leukoplakia, erythematous candidiasis, and gingival hyperplasia in renal transplant recipients. *Oral Surg Oral Med Oral Pathol.* 1994 Dec;78(6):718-26.
- Tyrzyk S, Sadlak-Nowicka J, Kedzia A, Bochniak M, Szumska-Tyrzyk B, Rutkowsky P. Clinical and mycological examination of oral mucosa in cyclosporine A treated patients after renal transplantation. *Przegl Lek.* 2004;61(5):467-72.
- Spolidorio LC, Spolidorio DMP, Massucato EMS, Neppelenbroek KH, Campanha NH, Sanches MH. Oral health in renal transplant recipients administered cyclosporine A or tacrolimus. *Oral Dis.* 2006 May;12(3):309-14.
- Sahebjamee M, Shahabi MS, Nikoobakht MR, Beitollahi JM, Mansourian A. Oral lesions in kidney transplant patients. *Iran J Kidney Dis.* 2010 Jul;4(3):232-6.
- Research, Science and Therapy Committee of the American Academy of Periodontology. Drug-Associated Gingival Enlargement. *J Periodontol.* 2004 Oct;75(10):1424-31.
- de la Rosa Garcia E, Mondragon Padilla A. The effect of mycophenolate mophetil and azathioprine on gingival overgrowth associated with cyclosporine A use in kidney transplant patients. *Nefrologia.* 2009;29(5):474-8.
- de Oliveira Costa F, Diniz Ferreira S, de Miranda Cota LO, da Costa JE, Aguiar MA. Prevalence severity, and risk variables associated with gingival overgrowth in renal transplant subjects treated under tacrolimus or cyclosporine regimens. *J Periodontol.* 2006 Jun;77(6):969-75.
- James JA, Marley JJ, Jamal S, Campbell BA, Short CD, Johnson RW, et al. The calcium channel blocker used with cyclosporine has an effect on gingival overgrowth. *J Clin Periodontol* 2000; 27:109-115.
- Ellis JS, Saymour RA, Steele JG, Robertson P, Butler TJ, Thomason JM. Prevalence of gingival overgrowth induced by calcium channel blockers: A community – based study. *J Periodontol.* 1999 Jan;70(1):63-7.
- Khocht A, Schneider LC. Periodontal management of gingival overgrowth in the heart transplant patient: A case report. *J Periodontol.* 1997 Nov;68(11):1140-6.
- Goldman KE. Dental management of patients with bone marrow and solid organ transplantation. *Dent Clin North Am.* 2006 Oct;50(4):659-76, viii.