

# Assessment of the postoperative effect of corneal cross-linking on keratoconus using the ABCD grading system

Aida Kasumović<sup>1</sup>, Ines Matoc<sup>2</sup>, Armin Kasumović<sup>2</sup>, Ivan Sabol<sup>3</sup>, Ivana Radman<sup>1</sup>, Iva Krolo<sup>1</sup>

**Purpose:** To monitor the changes in the ABCD grading system during a one-year follow-up after a corneal cross-linking (CXL) procedure. **Methods:** This prospective study included 30 eyes of 25 patients with keratoconus, who received the CXL treatment. The patients with a history of ocular trauma or surgery and other corneal pathology were excluded from the study. The patients were examined at the baseline visit and followed up at 3, 6, and 12 months after the CXL. All the patients underwent a standard CXL procedure with visual acuity and Scheimpflug tomography testing at each visit. The corneal parameters and ABCD grading were monitored throughout the follow-up period. **Results:** There were no significant changes of parameter A and anterior radius curvature (ARC) in the ABCD grading system. Parameters B and D showed progression postoperatively, with an improvement of parameter D on the final visit. Parameter C showed a statistically significant increase at all three post-CXL visits, but a constant gradual decrease in the value over time. **Conclusion:** The ABCD grading system can be very useful in monitoring the progression of keratoconus (KC), but it can also help in monitoring the efficacy of corneal cross-linking. The anterior surface parameters in the ABCD grading system did not show progression in the post-CXL period, and parameters C and D showed improvement and stability a year after the procedure.

**Key words:** ABCD grading system, corneal cross-linking, corneal topography, keratoconus, Pentacam

Keratoconus (KC), an ectatic corneal disease, is most commonly classified into four stages according to the Amsler-Krumeich Classification system, which is based on the mean corneal power, astigmatism, transparency, and thinnest corneal thickness.<sup>[1-7]</sup> A new classification system, the ABCD grading system, uses tomographic parameters and visual acuity to classify KC into five stages based on its anatomical and functional changes. It collects data in the 3.0 mm zone centered on the thinnest location of the cornea for A: anterior radius of curvature (ARC), B: posterior radius of curvature, C: corneal thickness, and D: best-corrected distance visual acuity (BCVA) [Fig. 1].<sup>[8]</sup>

## Methods

This prospective study was conducted at a tertiary eye-care center from 2018 to 2020. It included 30 eyes of 25 patients with KC, aged from 18 to 35 years, who received corneal CXL treatment at the same institution. After detailed information was provided, an informed consent form was signed by all the subjects. The study followed the tenets of the Declaration of Helsinki and all protocols were approved by the Ethics Committee of University Hospital Center. The aim of this study was to monitor the changes in the ABCD grading system during a 1-year follow-up after the corneal collagen cross-linking (CXL) procedure.

The exclusion criteria were patients under 18 years of age, corneal pachymetry less than 400  $\mu\text{m}$ , corneal scarring, history of ocular trauma, history of ocular surgery, and corneal pathology other than KC. The patients were treated according to the ectasia progression that was defined by a consistent change in at least two of the following parameters where the magnitude of the change is above the normal noise of the testing system: steepening of the anterior corneal surface, steepening of the posterior corneal surface, thinning and/or an increase in the rate of corneal thickness change from the periphery to the thinnest point.<sup>[9]</sup> As for the keratometry values, a steepening of 1D of the flattest K (K1), steepest K (K2), or maximum keratometry value (Kmax) in 1-year preoperative follow-up was considered KC progression.

After a detailed clinical examination, corneal CXL was performed. Under sterile conditions, the patient's eye was anesthetized, the pupil was constricted by multiple applications of topical 1% tetracaine in combination with 2% pilocarpine, and the corneal epithelium was brushed off manually in the central 9.0 mm zone. According to conventional Dresden protocol, MedioCROSS M (0.1% Riboflavin, 1.1% HPMC) was instilled every 2 min for 30 min, after which a 9-mm diameter beam of ultraviolet A (UV-A) radiance of 3 mW/cm<sup>2</sup> was

### Access this article online

#### Website:

www.ijo.in

#### DOI:

10.4103/ijo.IJO\_368\_21

### Quick Response Code:



<sup>1</sup>Department of Ophthalmology, University Hospital Center Sestre Milosrdnice, Zagreb, Croatia, <sup>2</sup>Department of Ophthalmology, Eye Polyclinic Dr. Sefić, Sarajevo, Bosnia and Herzegovina, <sup>3</sup>Division of Molecular Medicine, Rudjer Boskovic Institute, Zagreb, Croatia

**Correspondence to:** Dr. Aida Kasumović, Domobrnska Ulica 23, Zagreb, Croatia. E-mail: aidakasumovic1@hotmail.com

Received: 11-Feb-2021

Revision: 07-Jun-2021

Accepted: 20-Aug-2021

Published: 23-Dec-2021

This is an open access journal, and articles are distributed under the terms of the Creative Commons Attribution-NonCommercial-ShareAlike 4.0 License, which allows others to remix, tweak, and build upon the work non-commercially, as long as appropriate credit is given and the new creations are licensed under the identical terms.

**For reprints contact:** WKHLRPMedknow\_reprints@wolterskluwer.com

**Cite this article as:** Kasumović A, Matoc I, Kasumović A, Sabol I, Radman I, Krolo I. Assessment of the postoperative effect of corneal cross-linking on keratoconus using the ABCD grading system. Indian J Ophthalmol 2022;70:79-84.

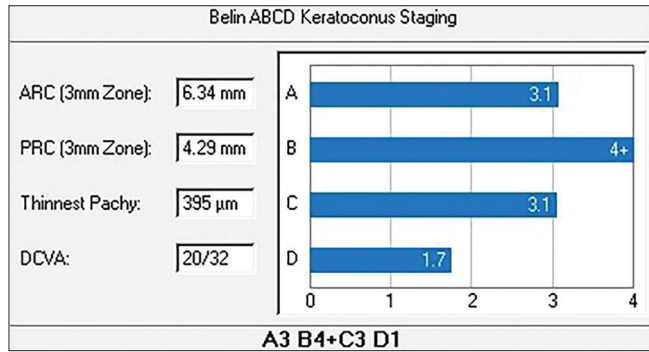
irradiated for 30 min in six 5-min intervals with a simultaneous drip of riboflavin.<sup>[10]</sup> After the procedure, the cornea was rinsed with a balanced salt solution and a silicone hydrogel

bandage contact lens was applied. Postoperatively, topical corticosteroids were used for 1–4 months, depending on the corneal haze.

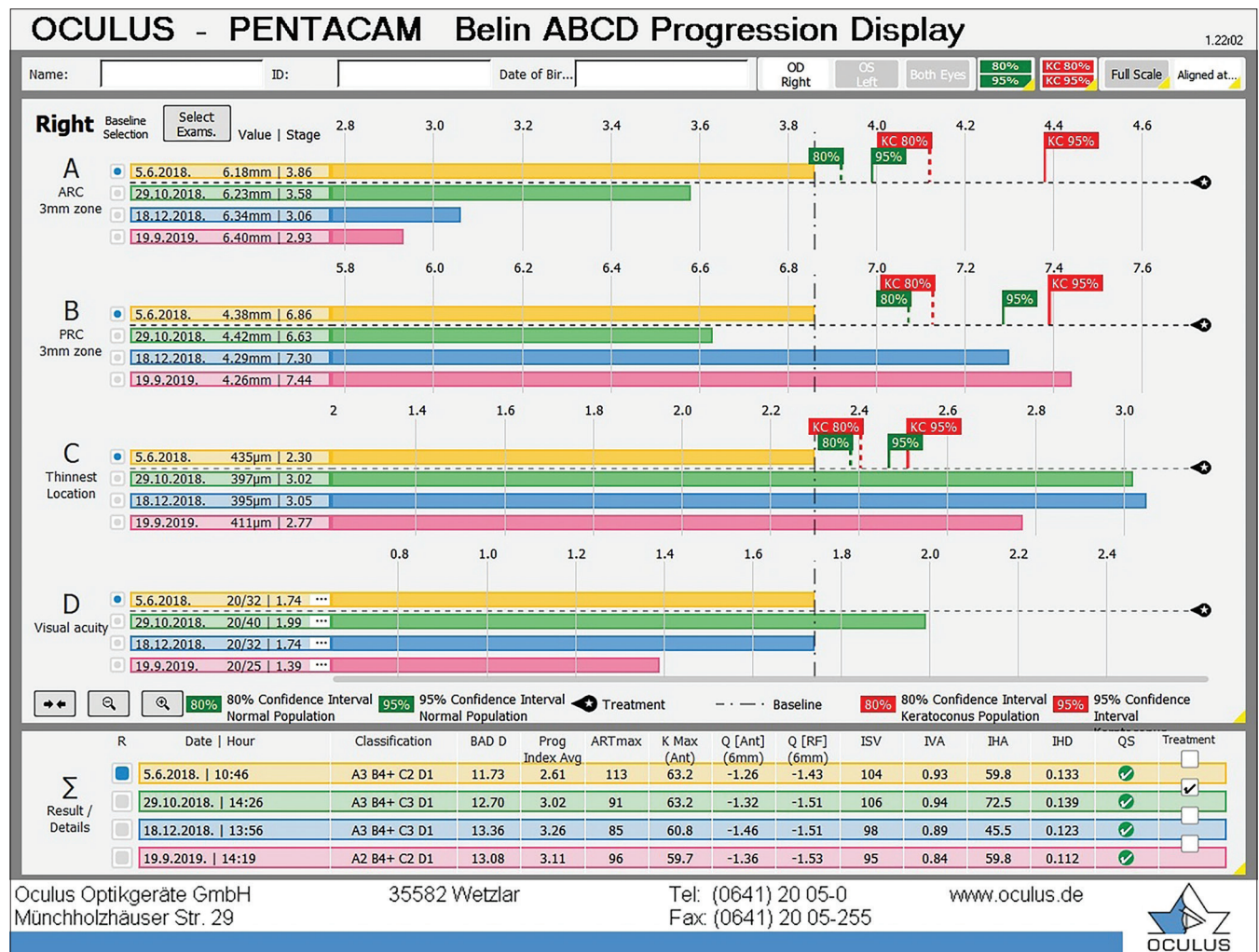
One preoperative (T0) and three postoperative examinations were performed in each patient. Postoperatively, the patients were scanned 3 months (T1), 6 months (T2), and a year (T3) after the procedure. At each visit, the participants underwent a slit-lamp examination, corneal tomography (Pentacam, OCULUS, Wetzlar, Germany), and visual acuity testing (Vista Vision Far-Pola, DMD MedTech charts, Italy).

On Pentacam, the Belin ABCD progression display was observed, which enabled the analysis of parameters A, B, C, and D, after manual input of the best-corrected visual acuity into the system for each visit [Fig. 2].

Other parameters that were monitored included anterior radius of curvature (ARC), posterior radius of curvature (PRC), thinnest location (TL), Ambrósio relational thickness maximum (ARTmax), maximal keratometry (K max), flat and steep keratometry values (K1 and K2), pachymetry apex (PA), topographic keratoconus classification (TKC),



**Figure 1:** Belin ABCD Keratoconus Staging Display allows objective evaluation of the cornea’s condition based on four measurements, graded 0–4. Above is a patient with advanced disease. The anterior and posterior surface show marked ectatic change (A3 and B4), accompanied by moderately advanced corneal thinning (C3) and visual acuity impairment (D1)



**Figure 2:** Belin ABCD Progression Display allows retrospective objective evaluation of corneal behavior and visual acuity after corneal cross-linking treatment. Data above the dashed line for each parameter show the preoperative value, while data below that line represent the postoperative values during the follow-up period



average pachymetric progression index (AIP), Belin/Ambrósio enhanced ectasia total deviation value (BAD D), and back and front elevation. Also, the topometric indices, including the index of surface variance (ISV), index of vertical asymmetry (IVA), index of height asymmetry (IHA), index of height decentration (IHD), keratoconus index (KI), center keratoconus index (CKI), and minimum sagittal curvature (Rmin) were analyzed [Fig. 3].

All the data were recorded in MS Office Excel tables and analyzed in Medcalc (v11.4.2 Medcalc Software, Ostend, Belgium). The normality was assessed by the Kolmogorov–Smirnov test. A repeated-measures of analysis of variance (ANOVA) or the Friedman test (non-parametric repeated-measures ANOVA) was used as appropriate to compare different time points (T0, T1, T2, T3). A *P* value of < 0.05 was considered to be statistically significant.

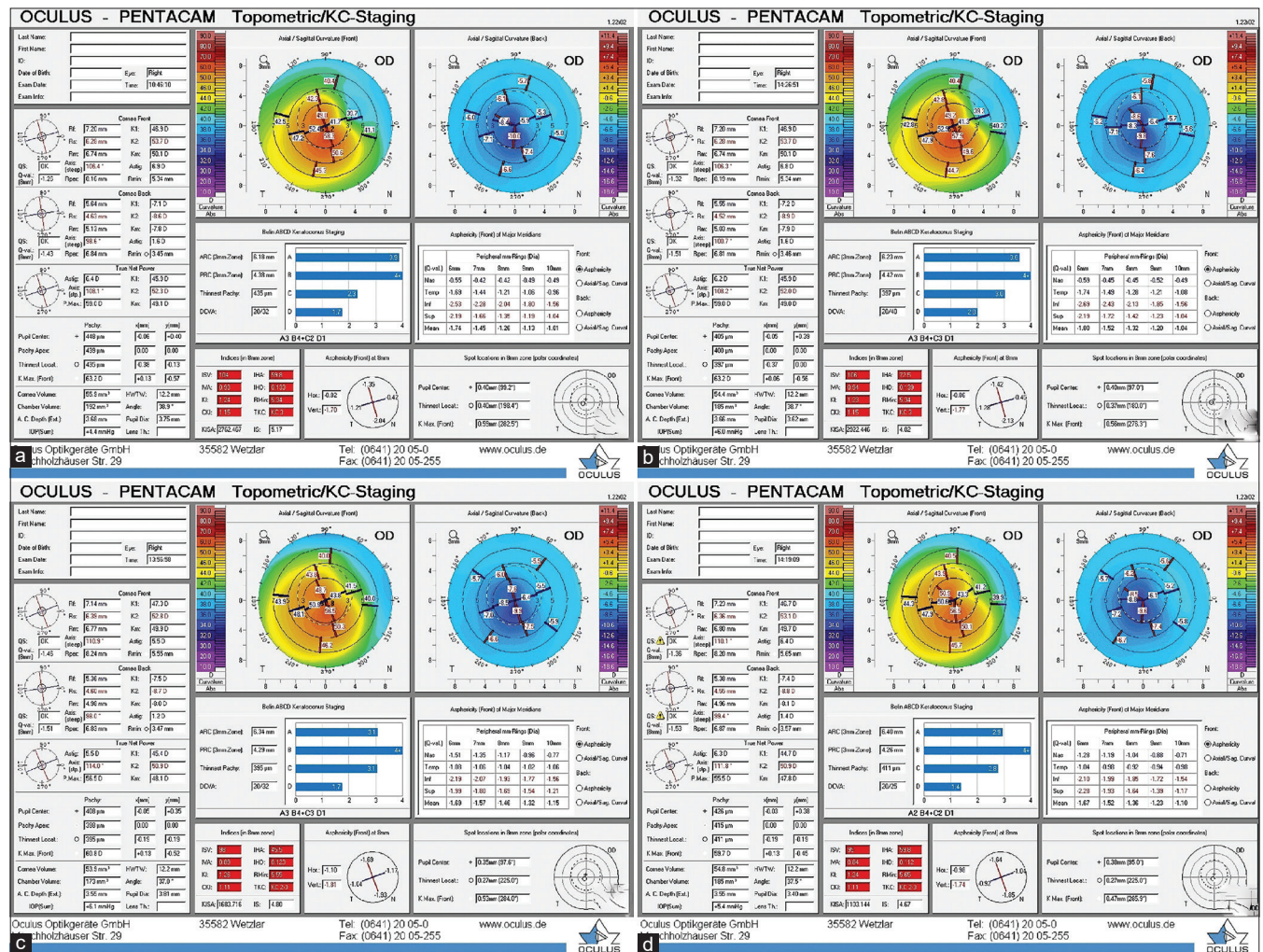
### Results

Thirty eyes of 25 subjects were recruited in this study, seven of which were females. The mean age of the subjects was  $26.3 \pm 5.9$  years. Based on the TKC system, 26.7% of the

examined eyes were classified as stage 1 (8 eyes), 36.7% as stage 2 (11 eyes), 26.3% as stage 3 (8 eyes), and 10% as stage 4 (3 eyes) preoperatively. Furthermore, 53.3% of the eyes had a preoperative best-corrected distance visual acuity (BCDVA) of 20/20, 33.3% had a BCDVA of 20/25, 10% had a BCDVA of 20/32, and 3.3% had a BCDVA of 20/40.

### ABCD grading parameters

The results referring to A, B, C, and D parameters, as well as the ARC and PRC, TL, and visual performance, are shown in Table 1. Parameter A and ARC did not show any significant change over a 12-month postoperative follow-up period (*P* = 0.263 and *P* = 0.331, respectively). Parameter B showed a significant increase of the mean value 3 months after the CXL, with similar values at the 12-month visit (*P* = 0.002). The mean PRC value showed a significant increase throughout the follow-up period (*P* = 0.001). A significant increase of parameter C was noted at all three post-CXL visits when compared to the baseline, but with a constant gradual decrease in value over time (*P* < 0.001). TL demonstrated significantly decreased values throughout the follow-up period (*P* = 0.001). Significant changes in parameter D were noted on the first



**Figure 3:** Topometric/KC-Staging Display with Belin ABCD Keratoconus Staging of the right eye with keratoconus. This display allows the analysis of corneal parameters and progression indices preoperatively (a), and 3 (b), 6 (c), and 12 months postoperatively (d); as well as the presentation of ABCD staging for each visit

post-CXL visit ( $P < 0.001$ ), returning to the preoperative value 1 year after the procedure.

### Tomographic indices and keratometry values

The results regarding keratometries and tomographic indices are shown in Table 2. Kmax, K1, K2, IHA, IHD, CKI, and front elevation values did not show a significant change throughout the follow-up period, and the values 1 year after CXL were similar to the baseline. The AIP showed a significant increase at all three postoperative visits ( $P < 0.001$ ), with a tendency toward stabilization a year after the procedure. The PA value demonstrated a significant decrease at all postoperative

visits ( $P < 0.001$ ), but it reverted to a nearly preoperative value a year after CXL. A significant change throughout the postoperative period was also found in BAD D and ART Max ( $P = 0.007$  and  $P < 0.001$ , respectively), and they significantly differed at the last visit in comparison with the baseline values ( $P < 0.005$  and  $P < 0.05$ , respectively).

ISV, IVA, KI, and Rmin showed a significant postoperative change at all visits ( $P = 0.016$ ,  $P = 0.008$ ,  $P = 0.048$  and  $P = 0.033$ , respectively), obtaining values similar to the baseline at the last visit. It was also noted that the back elevation significantly increased throughout the postoperative period ( $P = 0.01$ ).

**Table 1: The ABCD grading scale, corneal parameters required for the grading, and visual performance prior to the corneal cross-linking, and 3, 6, and 12 months postoperatively**

	Preoperative (mean±SD)	3-months post-CXL (mean±SD)	6-months post-CXL (mean±SD)	12-months post-CXL (mean±SD)	ANOVA P
A	1.97±1.44	2.06±1.62	1.87±1.49	2.05±1.59	0.263
B	3.6±2.25	<b>3.97±2.17**</b>	<b>3.85±2.29*</b>	3.92±2.4	<b>0.002</b>
C	1.4±0.77	<b>2.01±0.93***</b>	<b>1.73±0.88***</b>	<b>1.66±0.86***</b>	<b>&lt;0.001</b>
D	1.23±0.3	<b>1.41±0.36*</b>	1.33±0.34	1.21±0.27	<b>&lt;0.001</b>
ARC	6.92±0.57	6.91±0.65	6.96±0.6	6.96±0.59	0.331
PRC	5.1±0.61	<b>5.08±0.60**</b>	<b>5.1±0.61**</b>	<b>5.1±0.67*</b>	<b>0.001</b>
TL	478.27±40.41	<b>447.33±46.76***</b>	<b>460.93±43.05***</b>	<b>464.5±45.14***</b>	<b>0.001</b>
BCDVA	1 (0.80-1.00)	<b>0.8 (0.63-1.00) *</b>	<b>0.8 (0.63-1.00)*</b>	1 (0.80-1.00)	<b>&lt;0.001</b>

A – parameter A; B – parameter B; C – parameter C; D – parameter D; ARC – anterior radius of curvature; PRC – posterior radius of curvature; TL – thinnest location; BCDVA – best-corrected distance visual acuity. Statistically significant results on the repeated-measures ANOVA test are highlighted in bold. Significant Bonferroni adjusted *post hoc* test results comparing individual timepoints against preoperative values are highlighted with asterisk (\* $P < 0.05$ ; \*\* $P < 0.005$ ; \*\*\* $P < 0.0005$ ). For BCDVA median and IQR values are shown as well as the results of Friedman (non-parametric repeated ANOVA) test

**Table 2: Preoperative keratometries and tomographic indices, and their values 3, 6, and 12 months after the corneal cross-linking procedure**

	Preoperative (mean±SD)	3-months post-CXL (mean±SD)	6-months post-CXL (mean±SD)	12-months post-CXL (mean±SD)	ANOVA P
Kmax	52.94±5.62	53.1±5.24	52.44±5.06	52.33±5	0.053
K1	44.07±2.58	43.81±2.61	44.00±2.63	43.88±2.63	0.192
K2	47.56±3.3	47.53±3.29	47.33±3.22	47.56±3.78	0.819
Average pachymetric progression index	1.93±0.53	<b>2.39±0.7 ***</b>	<b>2.2±0.63 ***</b>	<b>2.25±0.75 **</b>	<b>&lt;0.001</b>
Belin/Ambrosio enhanced ectasia total deviation value (BAD D)	7.27±3.36	8.28±3.78	7.65±3.7	7.9±3.78 **	0.007
Ambrosio relational thickness maximum (ART Max)	163 (122.0-218.0)	<b>108 (91.0-158.0)*</b>	<b>148.5 (98.0-180.0)*</b>	<b>147.5 (113.0-167.0)*</b>	<b>&lt;0.001</b>
Pachymetry apex (PA)	492.8±36.15	<b>459.3±43.45***</b>	<b>476.53±42.3***</b>	<b>482.3±42.6*</b>	<b>&lt;0.001</b>
Index of height asymmetry (IHA)	29±19.51	29.53±21.62	30.07±19.07	25.73±16.52	0.608
Index of height decentration (IHD)	0.11±0.07	0.12±0.07	0.11±0.06	0.11±0.06	0.051
Index of surface variance (ISV)	79.4±40.69	84.9±39.7	78.73±36.5	77.8±35	<b>0.016</b>
Index of vertical asymmetry (IVA)	0.91±0.51	0.99±0.53	0.90±0.51	0.90±0.47	<b>0.008</b>
Keratoconus index (KI)	1.21±0.13	1.22±0.12	1.21±0.12	1.20±0.12	0.048
Center keratoconus index (CKI)	1.04±0.04	1.04±0.04	1.04±0.04	1.04±0.04	0.085
Minimum sagittal curvature (Rmin)	6.44±0.69	6.41±0.65	6.51±0.65	6.5±0.63	<b>0.033</b>
Front elevation	20.5±11.22	21.33±13.02	20.03±12.91	19.9±12.38	0.187
Back elevation	46.83±23.96	52.1±26.33	50.43±25.85	<b>51.83±28.74*</b>	<b>0.01</b>

K max – maximal keratometry; K1 – flat keratometry; K2 – steep keratometry. Statistically significant results on the repeated-measures ANOVA test are highlighted in bold. Significant Bonferroni adjusted *post hoc* test results comparing individual time points against preoperative values are highlighted with asterisk (\* $P < 0.05$ ; \*\* $P < 0.005$ ; \*\*\* $P < 0.0005$ ). For ART Max median and IQR values are shown as well as results of Friedman (non-parametric repeated ANOVA) test



## Discussion

There is no clear definition of corneal ectasia progression, according to the Global Consensus on Keratoconus and Ectatic Diseases.<sup>[9]</sup> So far, there are several methods that have been described to evaluate the progression of corneal ectasia or to monitor the efficacy of CXL. Early systems have utilized serial topographic analysis alone, whereas many newer systems have used complex keratometric indices to describe the progression.<sup>[11,12]</sup> The most commonly used parameter for detecting and monitoring ectatic progression, as well as the efficiency of CXL, is Kmax. However, studies have shown that Kmax fails to reflect the degree of ectasia, disregards the contribution of the posterior cornea to progression, and that ectatic progression can occur even without a change in Kmax.<sup>[13-15]</sup>

For the first time, in 2016, Belin and Duncan proposed a staging system that reflects changes in KC, which closely matched the previously used Amsler-Krumeich Classification. The ABCD grading system is able to reflect anatomical and functional corneal changes, by integrating not only the anterior and posterior corneal surface, and corneal thickness information, but also the visual acuity, into its final analysis and KC classification.<sup>[8]</sup>

As expected, this study showed an initial post-CXL increase of parameter C, which reflects the values of TL, and parameter D, which depicts the BCDVA. Both, however, returned to almost preoperative values a year after the treatment. Parameter A and ARC showed no change from the baseline over time. According to Bardan *et al.*,<sup>[16]</sup> parameter A showed a significant reduction over the first post-CXL year, while C and D significantly increased (parameter C was increased at all visits compared to the baseline, while parameter D showed an increase only a month post-CXL).

The present study showed a similar change in parameter C, while parameter D was increased initially, as noticed at 3 months post-CXL, but then stabilized and achieved the preoperative values. Those results are supported by the previous studies evaluating corneal thickness and visual acuity after CXL, where the stabilization of both parameters was achieved, according to some studies, even 6 months after the procedure.<sup>[17-20]</sup>

Sağlık *et al.*<sup>[21]</sup> showed significant regression in parameter A 1 year after CXL, which coincides with the results of Bardan,<sup>[16]</sup> but differs from the results of the current study. Bardan *et al.*<sup>[16]</sup> did not report any significant changes in parameter B over time. The results of our study differ since this variable showed a significant increase 1 year postoperatively. In the future, it might be useful to investigate how different modalities of CXL treatment and riboflavin solutions could affect the ABCD grading system. The ABCD grading system has been proven not only to be efficient in the assessment of KC progression and CXL efficacy but also in other therapeutic procedures, such as intracorneal ring implantations.<sup>[22]</sup>

Apart from the ABCD grading system, our study observed changes in keratometries and corneal indices of progression. The flattening of Kmax, which was shown in many previous studies, was not noticed in ours, although it should be emphasized that the values of Kmax remained stable over time.<sup>[16,21,23]</sup>

Many of the corneal tomographic indices can distinguish normal corneas from KC. However, in pre-keratoconus cases, the recommendation is to combine multiple indices, namely BAD D, ART, and the pachymetry progression index (PPI), along with clinical judgment in order to successfully risk-stratify each patient.<sup>[24]</sup> Hashemi *et al.*<sup>[25]</sup> showed high sensitivity and specificity of simultaneous evaluation of BAD D, 5<sup>th</sup> order vertical coma aberration, IVA, and ISV, especially when the pattern of the corneal curvature is normal in the detection of subclinical keratoconus. Another study showed excellent reliability of all parameters, apart from IHA. ARC, PRC, thinnest pachymetry, Kmax, CKI, KI, Rmin, and Progression Avg were the best repeatable parameters with relative repeatability values <2.5%.<sup>[26]</sup> The ISV and the IHD, which were proven to be the most sensitive and specific criteria in the diagnosis and progression of keratoconus out of the seven anterior surface Pentacam-derived topometric indices, did not show any worsening in the postoperative period of the present study, which may be interpreted as effective in halting the disease progression.<sup>[12]</sup>

A review of Motlagh *et al.*<sup>[24]</sup> states that the Ambrósio relational thickness measurement is calculated as the ratio between the thinnest point (TP) and the PPI. ART values include ART-Average (ART-Avg), ART-Minimum (ARTMin), and ART-Maximum (ART Max) and provide validated accuracy in identifying ectasia. ART Max was defined as TP/PPI Max.<sup>[27]</sup> Motlagh *et al.*<sup>[24]</sup> recommend the use of ART indices for the differentiation of keratoconic corneas with relatively normal central corneal thickness, and they found inconsistencies in the literature regarding the diagnostic accuracy of ART indices for pre-keratoconus cases. Our results showed a significant decrease in ART Max, which may be expected in the early postoperative period due to significant changes in corneal thickness and thickness profiles.

The limitations of the present study include a low number of eyes analyzed and a relatively short follow-up period. Many studies have proven that in order to obtain accurate postoperative outcomes, long-term follow-up is necessary since the corneal cross-linking can produce changes to the cornea many years after the procedure.<sup>[28,29]</sup>

The anterior surface parameters in the ABCD grading system did not show progression in the post-CXL period, and parameters C and D showed improvement and stability a year after the procedure. Although a progression of parameter B was noted after the CXL, it would be inaccurate to consider this as an indicator of the failed procedure. However, our study included a small sample size of only 30 eyes, which may contribute to the different outcomes if the sample was larger. Also, a longer postoperative follow-up period would be advised for further evaluation.

## Conclusion

The ABCD grading system provides a good insight into the KC disease severity, taking into account not only the anterior, but also posterior corneal curvatures, corneal thickness profiles, and combining them with functional changes in visual acuity. It can be useful in monitoring the KC progression and efficacy of the CXL procedure.

### Financial support and sponsorship

Nil.

### Conflicts of interest

There are no conflicts of interest.

### References

- Rosen ES. Keratoconus. *J Cataract Refract Surg* 2012;38:927-8.
- Amsler M. Keratocone classique et keratocone fruste; arguments unitaires. *Ophthalmologica* 1946;111:96-101.
- Rabinowitz YS, Rasheed K. KISA % index: A quantitative videokeratography algorithm embodying minimal topographic criteria for diagnosing keratoconus. *J Cataract Refract Surg* 1999;25:1327-35.
- Maeda N, Klyce SD, Smolek MK, Thompson HW. Automated keratoconus screening with corneal topography analysis. *Invest Ophthalmol Vis Sci* 1994;35:2749-57.
- Alió JL, Shabayek MH. Corneal higher order aberrations: A method to grade keratoconus. *J Refract Surg* 2006;22:539-45.
- McMahon TT, Szczotka-Flynn L, Barr JT, Anderson RJ, Slaughter ME, Lass JH, *et al.* A new method for grading the severity of keratoconus: The Keratoconus Severity Score (KSS). *Cornea* 2006;25:794-800.
- Li X, Yang H, Rabinowitz YS. Keratoconus: Classification scheme based on videokeratography and clinical signs. *J Cataract Refract Surg* 2009;35:1597-603.
- Belin MW, Duncan JK. Keratoconus: The ABCD grading system. *Klin Monbl Augenheilkd* 2016;233:701-77.
- Gomes JA, Tan D, Rapuano CJ, Belin MW, Ambrósio R Jr, Guell JL, *et al.* Global consensus on keratoconus and ectatic disease. *Cornea* 2015;34:359-69.
- Choi M, Kim J, Kim EK, Seo KY, Kim TI. Comparison of the conventional dresden protocol and accelerated protocol with higher ultraviolet intensity in corneal collagen cross-linking for keratoconus. *Cornea* 2017;36:523-9.
- Choi JA, Kim MS. Progression of keratoconus by longitudinal assessment with corneal topography. *Invest Ophthalmol Vis Sci* 2012;53:927-35.
- Kanellopoulos AJ, Asimellis G. Revisiting keratoconus diagnosis and progression classification based on evaluation of corneal asymmetry indices, derived from Scheimpflug imaging in keratoconic and suspect cases. *Clin Ophthalmol* 2013;7:1539-48.
- O'Brart DP, Chan E, Samaras K, Patel P, Shah SP. A randomised, prospective study to investigate the efficacy of riboflavin/ultraviolet A (370 nm) corneal collagen cross-linkage to halt the progression of keratoconus. *Br J Ophthalmol* 2011;95:1519-24.
- de Sanctis U, Loiacono C, Richiardi L, Turco D, Mutani B, Grignolo FM. Sensitivity and specificity of posterior corneal elevation measured by Pentacam in discriminating keratoconus/subclinical keratoconus. *Ophthalmology* 2008;115:1534-9.
- Tomidokoro A, Oshika T, Amano S, Higaki S, Maeda N, Miyata K. Changes in anterior and posterior corneal curvatures in keratoconus. *Ophthalmology* 2000;107:1328-32.
- Bardan AS, Kubrak-Kisza M, Kisza KJ, Nanavaty MA. Impact of classifying keratoconus location based on keratometry or pachymetry on progression parameters. *Clin Exp Optom* 2020;103:312-9.
- Kasumovic SS, Pavljasevic S, Dacic-Lepara S, Jankov M. The results of corneal cross-linking in the treatment of keratoconus. *Med Arch* 2013;67:372-3.
- Zarei-Ghanavati S, Khakshour H, Vejdani M, Ghooshkhaneh H, Vejdani A. Evaluation of changes in visual acuity, contrast sensitivity and aberrations in patients with keratoconus after corneal collagen cross-linking. *J Ophthalmic Vis Res* 2017;12:260-4.
- Zhang X, Sun L, Chen Y, Li M, Tian M, Zhou X. One-year outcomes of pachymetry and epithelium thicknesses after accelerated (45 mw/cm<sup>2</sup>) transepithelial corneal collagen cross-linking for keratoconus patients. *Sci Rep* 2016;6:32692.
- Greenstein SA, Shah VP, Fry KL, Hersh PS. Corneal thickness changes after corneal collagen crosslinking for keratoconus and corneal ectasia: One-year results. *J Cataract Refract Surg* 2011;37:691-700.
- Sağlık A, Işık MU. Progression analysis with ABCD grading system following corneal collagen cross-linking in keratoconus. *Beyoglu Eye J* 2019;4:156-62.
- Sedaghat MR, Momeni-Moghaddam H, Belin MW, Akbarzadeh R, Sakhaee M, Armanfar F, *et al.* Anatomical and visual effects of the myring implantation measured by the ABCD keratoconus grading system. *Eye Contact Lens* 2020;46:52-6.
- Kasai K, Kato N, Konomi K, Shinzawa M, Shimazaki J. Flattening effect of corneal cross-linking depends on the preoperative severity of keratoconus. *Medicine (Baltimore)* 2017;96:e8160. doi: 10.1097/MD.0000000000008160.
- Motlagh MN, Moshirfar M, Murri MS, Skanchy DF, Momeni-Moghaddam H, Ronquillo YC, *et al.* Pentacam® corneal tomography for screening of refractive surgery candidates: A review of the literature, Part I. *Med Hypothesis Discov Innov Ophthalmol* 2019;8:177-203.
- Hashemi H, Beiranvand A, Yekta A, Maleki A, Yazdani N, Khabazkhoob M. Pentacam top indices for diagnosing subclinical and definite keratoconus. *J Curr Ophthalmol* 2016;28:21-6.
- Neuhann S, Schuh A, Krause D, Liegl R, Schmelter V, Kreutzer T, *et al.* Comparison of variables measured with a Scheimpflug device for evaluation of progression and detection of keratoconus. *Sci Rep* 2020;10:19308.
- Ambrósio R Jr, Caiado AL, Guerra FP, Louzada R, Sinha RA, Luz A, *et al.* Novel pachymetric parameters based on corneal tomography for diagnosing keratoconus. *J Refract Surg* 2011;27:753-8.
- Noor IH, Seiler TG, Noor K, Seiler T. Continued long-term flattening after corneal cross-linking for keratoconus. *J Refract Surg* 2018;34:567-70.
- Kymionis GD, Grentzelos MA, Liakopoulos DA, Paraskevopoulos TA, Klados NE, Tsoulnaras KI, *et al.* Long-term follow-up of corneal collagen cross-linking for keratoconus--The Cretan study. *Cornea* 2014;33:1071-9.